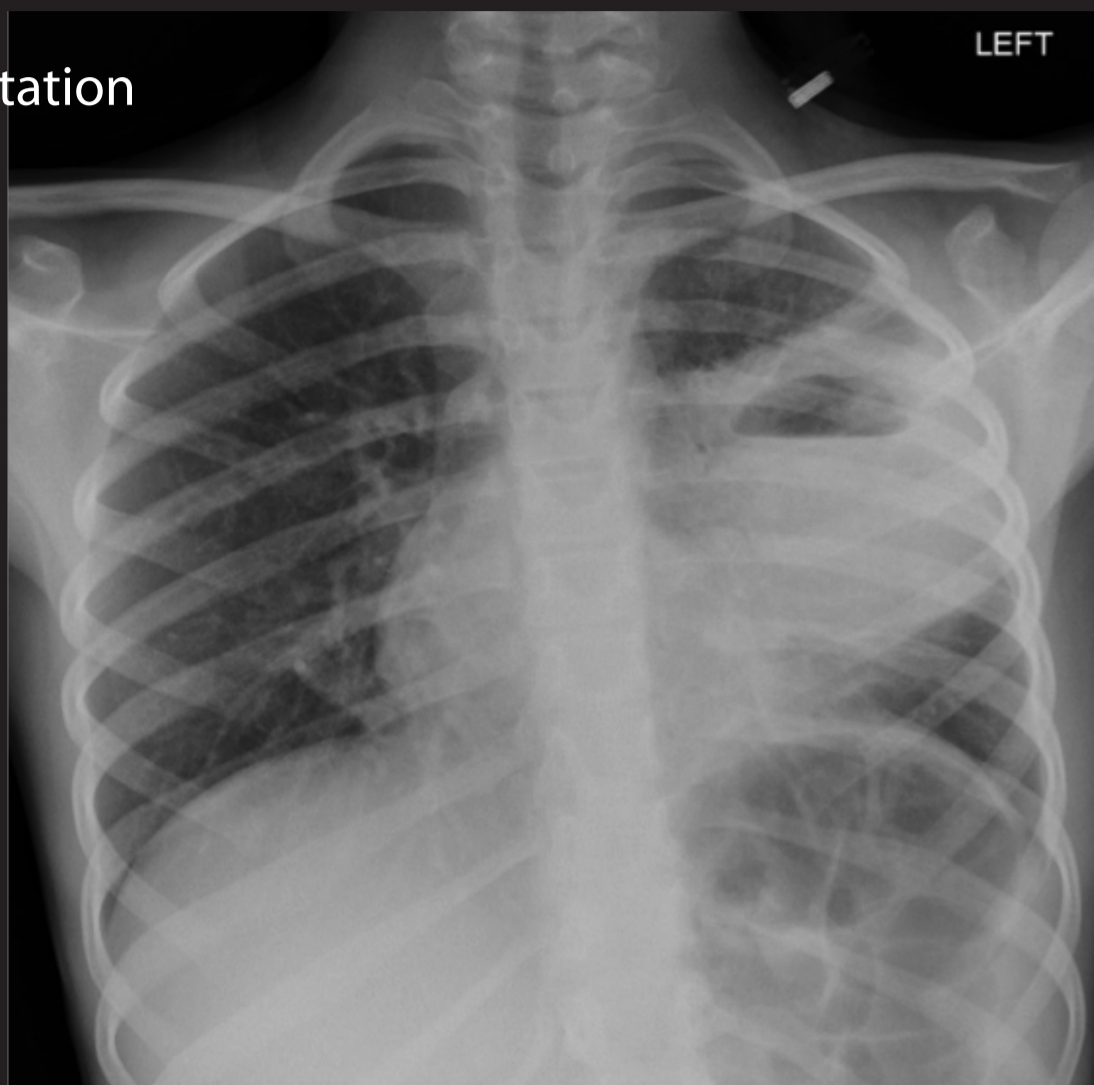


Lung abscess.

A 9 year old boy presented with chest pain and was found to have a lung abscess. This responded to antibiotics, as witnessed by the repeat chest X-ray taken 2 months later.

Chest X-ray at presentation



Air-fluid  
level of  
abscess

Chest X-ray 2 months later

